

Giant cell arteritis: A new perspective on investigations and diagnostic criteria

Amol Sagdeo¹, Ayman Askari¹, Hana Morrissey^{2,*} and Patrick A. Ball²

¹The Robert Jones & Agnes Hunt Orthopaedic Hospital NHS Foundation Trust, SY10 7AG, UK;

²School of Pharmacy, University of Wolverhampton, WV1 1LY, UK.

ABSTRACT

Giant cell arteritis (GCA) is a common form of granulomatous inflammation of large blood vessels. It can cause irreversible blindness in nearly 20% of untreated cases. It has an incidence of 15-30 per 100,000 persons aged 50 years and over in North American and European countries. GCA is a medical emergency and requires early confirmation of diagnosis and initiation of treatment. Recent development in non-invasive imaging modalities, with higher sensitivities and specificities than temporal artery biopsy (TAB), improved the standard for GCA diagnosis. The recent updates on British Society for Rheumatology guidelines elaborated on the role of ultrasound (US) in the diagnosis of GCA and use of the guidelines provides a new approach for GCA confirmatory diagnosis. A search was conducted using EMBASE and Medline databases to identify recent published research on the diagnosis of GCA. Only human studies published in English between 2010 to 2020 were considered in this systematic narrative review. This review also summarises the evidence available for non-invasive imaging and recommends an approach combining the recently published algorithm for diagnosis decision making of cranial GCA using scoring system. This review proposes a combined approach to use a clinical diagnostic decision making in suspected cranial GCA and use the scoring system based on the clinical history, examination findings, laboratory results and the imaging results combined to give a score to

diagnose GCA from other vasculitides. The approach to investigate a case of GCA needs to be modified and should include newer imaging techniques available and new diagnostic criteria should be used in combination with the rapid access pathways for clinical decision.

KEYWORDS: giant cell arteritis, temporal artery biopsy, ultrasound, magnetic resonance imaging, positron emission tomography, 18F-fluorodeoxyglucose positron emission tomography, vasculitis.

INTRODUCTION

Giant cell arteritis (GCA) is common in the Northern European population but is rare in African Americans, native Americans, and Asians [1]. The reports from India are either in the form of small case series or single case reports. The single largest Indian study that reviewed retrospective data from various small case series concluded that GCA occurred almost a decade earlier, had a male predominance, a low rate of temporal artery biopsy (TAB) positivity, and the higher incidence of ophthalmological complications [2]. GCA has annual incidence of 15-25 per 100 000 individuals >50 years in Caucasians with female to male ratio of 2-4:1 [3].

GCA affects large-to-medium-sized blood vessels, mainly the branches of carotid artery, leading to anterior ischaemic optic neuropathy and irreversible blindness. The treatment involves mainly high dose glucocorticoids initiated as early as possible to prevent blindness and continued for a significant period, which will usually precipitate metabolic

*Corresponding author: hana.morrissey@wlv.ac.uk

complications [4]. Disease Modifying Antirheumatic Drugs (DMARDs), and Biologicals (Anti-IL6) have been successfully used in resistant cases (GIACTA trail) [5].

Methods

A systematic literature review (SLR) was carried out using the resources available on UK NICE Healthcare Databases Advanced Search (HDAS) platform [6] searching the EMBASE[®] and Medline[®] databases. Only human studies involving adults were reviewed, including articles published in the English language between 2010 to 2020. Some relevant older cross-referencing articles were also included in this review. From >10000 search results, 751 were selected as relevant articles. Further review homed in on 19 relevant and recent publications. The review also discussed practice points and guidelines of relevant professional associations. The grading used for the quality of evidence in this review was based on the BMJ best-practice guidance for the grading of research data. This is further defined below.

Clinical features

The typical manifestations of GCA include headache, constitutional symptoms, symptoms of polymyalgia rheumatica (PMR), scalp pain or tenderness, jaw claudication, and visual disturbances [2]. New onset of temporal headache is the most common, and jaw claudication is the most specific symptom of GCA [7, 8]. Scalp tenderness and visual disturbances are also common, while scalp necrosis and tongue claudication or necrosis occur less frequently. Cranial ischaemic events leading to blindness occur in 15-20% of cases and transient ischaemic attacks (TIA)s or strokes occur in 3-7% cases. Hence GCA is considered as medical emergency [8]. Extracranial GCA symptoms occur in 20-80% cases, ranging from limb claudication, bruits and reduced or absent pulses. Non-specific systemic symptoms are fatigue, low grade fever and weight loss [3]. PMR symptoms are characterised by pain and stiffness in the hip and shoulder girdle and occur in 40-60% of cases. It is important to recognise that GCA occurs in 16-21% of PMR diagnosed cases [9, 10], and patients with PMR who develop a new headache should be immediately seen.

Investigations

Inflammatory markers

Most patients with GCA exhibit high levels of inflammatory markers except in patients with localised disease and without constitutional symptoms, in whom ESR and CRP may be normal. Patients with normal markers are at high risk of developing blindness [3].

Temporal artery biopsy (TAB)

Histopathology of the temporal artery is considered to be the gold standard for the diagnosis of GCA [10]. Disruption of the internal elastic membrane, mononuclear cell infiltration, and granulomas with multinucleated giant cells located close to the intima-media junction are the characteristic findings in the biopsy. Considering the segmental nature of involvement of the temporal artery, TAB is found normal in approximately 10-30% of cases [11]. TAB should be performed within 1 week of the initiation of treatment to improve sensitivity. The optimal length of the temporal artery segment is around 1.5 cm to allow for the 10% shrinkage post-formalin fixation [12]. The site of biopsy should be at the most symptomatic, tender area. Simultaneous biopsy from the contralateral side is reported to increase diagnostic yield by only 4-13% and hence is not routinely advised [13].

TAB has specificity of 100% for GCA but its sensitivity can be as low as 39% due to skip lesions. Although it is a low-risk procedure, with an adverse outcome rate around 0.5%, the most serious complications being facial nerve injury [14] and scalp necrosis post procedure, hence the preference for a less invasive and more sensitive option [15].

Role of ultrasound in diagnosis of cranial GCA

TAB has been the gold-standard, but this view has changed since the development of improved diagnostic accuracy with ultrasound (US) of temporal artery, compared to biopsy, with the advantage of access to the entirety of both superficial temporal arteries. All recent diagnostic accuracy studies have focussed on the role of US (16 studies) or MRI (7 studies) or role of positron emission tomography with 2-deoxy-2-[fluorine-18]fluoro-D-glucose (FDG-PET) and computerised tomography-angiography for GCA diagnosis [4].

US was used first time for temporal arteries by Schmidt *et al.* in 1997 to describe the ‘halo sign’, which is presence of homogeneous, hypoechoic wall thickening in the affected part of artery [16]. With modern US machines providing resolution of down to 0.1 mm, the identification of ‘Halo signs’ >0.29-0.42 mm in the temporal arteries and >1.0 mm in the axillary arteries plus compression signs, are regarded by the Outcome Measures in Rheumatology (OMERACT) Large Vessel Vasculitis Ultrasound Working Group as the most important US findings suggestive of vasculitis. ‘Halo sign’ is the minimum requirement to diagnose GCA [17]. ‘Compression sign’, which is incompressibility of temporal artery upon application of pressure with the US probe, is another useful sign. This may have 100% positive predictive value for GCA [18]. Table 1 summarises all the evidence available for US as a confirmatory diagnostic test to be performed in all the patients with suspected cases of GCA [4].

Thus, US has higher sensitivity but lower specificity than biopsy for diagnosis of GCA, is cost effective and provides an alternative to reduce the number of patients who require TAB [25]. Overall, the pooled positive and negative likelihood ratios for US appear to support its use either for ruling out GCA in low-probability cases or for confirming GCA in high-probability cases (Figure 1). US of the axillary arteries might add extra diagnostic information to US of the temporal arteries [24].

Timing of the ultrasound

Detection of the ‘Halo sign’ diminishes rapidly after treatment and may disappear in 2-10 weeks [31]. Hence US should be performed as soon as possible to the suspicion of the diagnosis. The European League against Rheumatism (EULAR) recommends US of the temporal +/- axillary arteries as the first imaging modality in patients with a suspicion of predominantly cranial GCA [31].

Table 1. Summary of US studies for GCA diagnosis.

Total number of studies	Total suspected GCA patients	Total diagnosed GCA patients	What is compared with what?	Pooled sensitivity	Pooled specificity	Quality of Evidence QoE
7 [19-25]	519	169	US Halo sign Vs clinical diagnosis of GCA	79% (95% CI 73,84)	94% (95% CI 90,96)	+++ (Downgraded as risk of bias in 4 out of 7 studies)
5 [23-27]	185	57	US Halo sign Vs Temporal Artery Biopsy	74% (95% CI 63,83)	81% (95% CI 73,88)	+(Downgraded as risk of bias in all 5 studies)
2 [18, 19]	140	67	US Compression sign Vs ACR based diagnostic criteria for GCA)	79% (95% CI 67,88)	100% (95% CI 95,100)	++ (Downgraded as risk of bias in 1 of the studies, both were for the same study and ACR criteria for GCA was used as a reference in both the studies)
3 [25, 28, 29]	560	327	US abnormality (Halo sign, stenosis, or occlusion) Vs clinical diagnosis	61% (95% CI 56,67)	86% (95% CI 81,90)	++ (Downgraded as risk of bias in all 3 studies and for inconsistency)
4 [25, 28-30]	563	180	US abnormality (Halo sign, stenosis or occlusion) Vs Temporal Artery Biopsy	81% (95% CI 74,86)	74% (95% CI 70,79)	++ (Downgraded as risk of bias in 3 out of 4 studies and for imprecision)

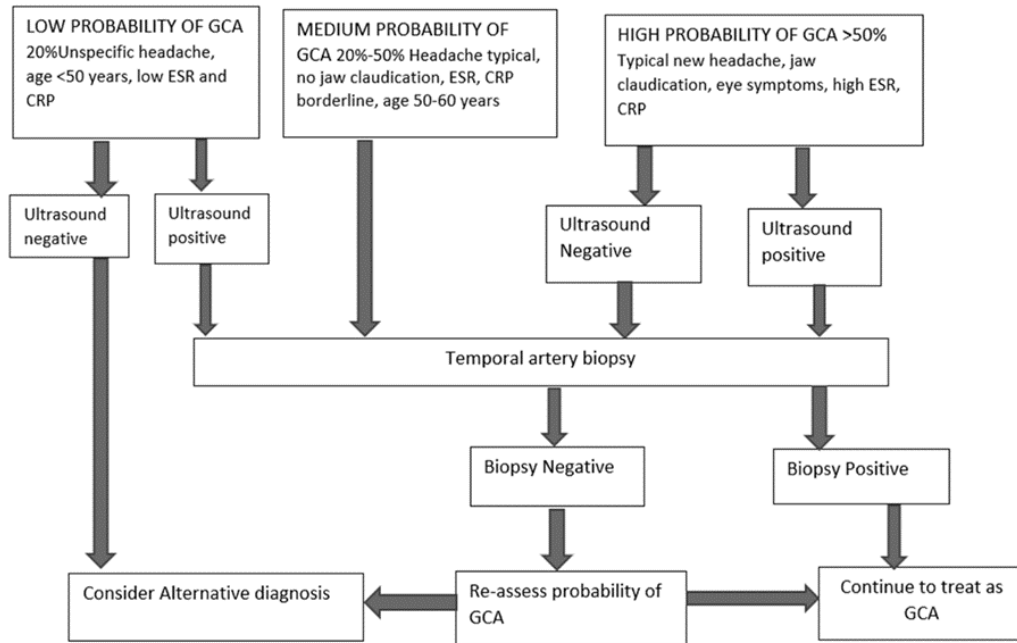


Figure 1. An algorithm for decision making the diagnosis of cranial GCA.

Advantages and limitations of US

1. Non-invasive technique
2. Ability to assess several arterial territories during the same evaluation
3. Ability to provide immediate results
4. Can be repeated and could be more accessible in certain hospitals

However, US is highly dependent on the operator skills and capabilities of the equipment available.

Role of other imaging modalities in cranial GCA

Magnetic resonance imaging

MRI can assess wall thickness and contrast enhancement in the temporal, occipital and intracranial arteries in patients with GCA. A normal MRI of the intracranial arteries has been strongly associated with a normal TAB; hence it could be used as the initial diagnostic tool, with TAB reserved only for cases with abnormal results. After starting Glucocorticoid treatment MRI should be done within 5 days to avoid reduction in sensitivity (Table 2) [32].

Thus, MRI has a better negative predictive value, but false positives could result and hence cannot be first choice for a confirmatory test for GCA. It is also

more time-consuming, more expensive and in most centres, less available than US, can precipitate adverse reactions to the contrast media and can be a problem for claustrophobic patients [37].

Selection of the most appropriate confirmatory diagnostic test(s) therefore requires an assessment of the pre-test probability as outlined above [38]; if both US and TAB are available, an approach is suggested in Figure 1.

Patients with suspected GCA should have a confirmatory diagnostic test. This could be either a TAB at least 1 cm in length or an ultrasound of the temporal and axillary arteries, or both. QoE: +++ [4].

Large vessel-GCA: tests for evaluation of Aorta and its branches in GCA (Tables 3 and 4).

Advantages and limitation of PET

Due to its distinctive uptake pattern of FDG (Shoulders, hips, spine etc), F-FDG-PET can contribute to the diagnosis of concomitant PMR. F-FDG uptake in the sternoclavicular joints is one of the characteristic findings in patients with PMR as well as the uptake in the shoulders, ischial tuberosities, and greater trochanters. “Y”-shaped spinous process uptake may be one of the specific findings for PMR [41]. The ability to diagnose

Table 2. Summary of studies for MRI as a diagnostic test for GCA diagnosis.

Total number of studies	Total suspected GCA patients	Total diagnosed GCA patients	What is compared with what?	Pooled sensitivity	Pooled specificity	Quality of Evidence QoE
6 [32-37]	500	268	Cranial artery MRI (vessel wall oedema and contrast enhancement) Vs clinical diagnosis of GCA	75% (95% CI 69,80)	89% (95% CI 84,93)	++ (Downgraded for risk bias in 5 out of 6 studies and five out six were done by same research group)
5 [32-35, 37]	397	171	Cranial artery MRI (vessel wall oedema and contrast enhancement) Vs Temporal artery biopsy	94% (95% CI 90,97)	79% (95% CI 73,84)	+ (Downgraded for the risk of bias in all 5 studies, for inconsistency and for publication bias)

Table 3. Summary of studies for FDG-PET as a diagnostic test for LV-GCA diagnosis.

Total number of studies	Total suspected GCA patients	Total diagnosed GCA patients	What is compared with what?	Pooled sensitivity	Pooled specificity	Quality of Evidence QoE
1 [39]	24	15	FDG-PET Vs Clinical diagnosis	67% (95% CI 38,88)	100% (95% CI 66,100)	++ (Downgraded because of indirectness and publication bias)
1 [40]	69	13	FDG-PET uptake of glucose in thorax and legs Vs temporal artery biopsy	77% (95%CI 46,95)	66% (95% CI 52,78)	+ (Downgraded because of the risk of bias, indirectness and imprecision)

Table 4. Table summarising all the available studies for CTA (CT angiogram) as a diagnostic test for LV-GCA diagnosis.

Total number of studies	Total suspected GCA patients	Total diagnosed GCA patients	What is compared with what?	Pooled sensitivity	Pooled specificity	Quality of Evidence QoE
1 [39]	24	15	CTA Vs Clinical diagnosis	73% (95% CI 45,92)	78% (95% CI 40,97)	++ (Downgraded because of the risk of publication bias and indirectness)

alternative conditions such as malignancy or infections is the most important advantage of PET. It is also useful in patients with unexplained fever with high CRP and ESR without any typical symptoms of GCA who fall into the category of pyrexia of unknown origin.

Limitations of FDG-PET

The diagnostic performance of PET reduces sharply between third and tenth day after initiation of GCA treatment. Arranging PET scan at such a short notice may well be challenging in many centres. High costs and exposure to radiation are other major limitations. A need for blood glucose levels <7 mmol/l (126 mg/dl) for better sensitivity can be difficult to achieve in poorly controlled diabetic patients [3].

New diagnostic criteria for GCA

American College of Rheumatology (ACR) 1990 criteria were developed to differentiate GCA from other vasculitides, not from non-vasculitis conditions and have performed poorly when used for the latter [3].

Since 1990 imaging technology has considerably improved allowing better assessment of cranial and large vessels affected in GCA. Consequently, the current ACR diagnostic criteria should be updated to incorporate the newer imaging modalities available such as the use of Doppler US. Diagnostic and classification criteria for differentiating GCA from other vasculitides, have been published with differently weighted criteria for GCA, abnormalities on temporal artery examination, high levels of inflammatory markers, abnormal TAB and specific imaging patterns (Halo sign on US or FDG-PET activity throughout aorta) [42]. Their criteria for classification of GCA are as below:

All patients must have a diagnosis of vasculitis and age ≥ 40 years at the time of diagnosis. Patients must have ≥ 6 points of inclusion criteria to meet the threshold for classification. These criteria include

1. Clinical features (2 points each): Morning stiffness in shoulders or neck, sudden visual loss, jaw or tongue claudication, new temporal headache, and scalp tenderness.
2. Temporal artery examination findings: Reduced pulse or tenderness (1 point).

3. Raised Inflammatory Markers: ESR ≥ 50 mm/h or CRP ≥ 10 mg/L (3 points).
4. TAB (5 points for definite vasculitis; 2 points for possible vasculitis).
5. US findings criteria include temporal artery halo sign (5 points),
6. F-FDG-PET criteria: Bilateral axillary involvement (3 points), and (FDG-PET) activity throughout aorta (3 points).

This new classification criteria used along with the decision making algorithm discussed above will result in rapid confirmation of the diagnosis of GCA.

CONCLUSION

As per ACR criteria for the diagnosis of GCA, TAB was desirable in every case of suspected GCA. This has been changed in view of improved diagnostic accuracy of US compared to biopsy and the advantage of access to both superficial temporal arteries in their entirety. TAB and US differ in their positive and negative likelihood ratios for GCA, with biopsy having relatively greater 'rule-in' value and ultrasound having relatively greater 'rule-out' value. Non-invasive imaging techniques are recommended in the absence of TAB for confirming the diagnosis of GCA [43]. Development of fast track pathways using new imaging techniques have resulted in a reduction in the risk of permanent blindness by 88% in the fast track groups, although risk of visual disturbance remained same in historical and fast track groups [42, 44]. Fast track pathways based on the new classification criteria and decision-making algorithm as shown in Figure 1 should result in reducing the delay in diagnosis of GCA.

We recommend that a combined approach, using a clinical diagnostic decision-making algorithm in suspected Cranial GCA and use the GCA classification criteria based on the scoring system, should replace the historical ACR 1990 criteria for the diagnosis of GCA. This new approach may require further validation.

Grades of the evidence were calculated as per BMJ best practice guidance [45]:

- + or Very low: The true effect is probably markedly different from the estimated effect
- ++ or Low: The true effect might be markedly different from the estimated effect

+++ or Moderate: The authors believe that the true effect is probably close to the estimated effect
 ++++ or High: The authors have a lot of confidence that the true effect is similar to the estimated effect

CONFLICT OF INTEREST STATEMENT

The authors have no conflict of interests to disclose.

FUNDING

No external funding

AUTHORS' CONTRIBUTIONS

Authors 1 and 2 conducted the review, all authors completed the first draft and authors 3 and 4 reviewed and revised the manuscript and completed the final submission.

REFERENCES

- Gonzalez-Gay, M. A., Garcia-Porrúa, C., Llorca, J., Gonzalez-Louzao, C. and Rodriguez-Ledo, P. 2001, *Semin. Arthritis Rheum.*, 30(4), 249-256.
- Sharma, A., Sagar, V., Prakash, M., Gupta, V., Khaire, N., Pinto, B., Dhir, V., Bal, A., Aggarwal, A., Kumar, S., Sharma, K., Rathi, M., Das, A., Singh, R., Singh, S. and Gupta, A. 2015, *Neurol. India*, 63(5), 681-686.
- Ponte, C., Martins-Martinho, J. and Luqmani, R. A. 2020, *Rheumatology (Oxford)*, 59, iii5-iii16.
- Mackie, S. L., Dejaco, C., Appenzeller, S., Camellino, D., Duftner, C., Gonzalez-Chiappe, S., Mahr, A., Mukhtyar, C., Reynolds, G., De Souza, A. W. S., Brouwer, E., Bukhari, M., Buttgerit, F., Byrne, D., Cid, M. C., Cimmino, M., Direskeneli, H., Gilbert, K., Kermani, T. A., Khan, A., Lanyon, P., Luqmani, R., Mallen, C., Mason, J. C., Matteson, E. L., Merkel, P. A., Mollan, S., Neill, L., Sullivan, E. O., Sandovici, M., Schmidt, W. A., Watts, R., Whitlock, M., Yacyshyn, E., Ytterberg, S. and Dasgupta, B. 2020, *Rheumatology (Oxford)*, 59(3), e1-e23.
- Stone, J. H., Tuckwell, K., Dimonaco, S., Klearman, M., Aringer, M., Blockmans, D., Brouwer, E., Cid, M. C., Dasgupta, B., Rech, J., Salvarani, C., Schett, G., Schulze-Koops, H., Spiera, R. and Unizony, S. H., Collinson, N. 2017, *N. Engl. J. Med.*, 377(4), 317-328.
- National Institute of Clinical Excellence (NICE), Healthcare Databases Advanced Search (HDAS). Accessed 17/07/2020. Available at: <https://hdas.nice.org.uk/>.
- Peral-Cagigal, B., Pérez-Villar, Á., Redondo-González, L., García-Sierra, C., Morante-Silva, M., Madrigal-Rubiales, B., and Verrier-Hernández, A. 2018, *Medicina Oral*, 23(3), e290-e294.
- Smith, J. H. and Swanson, J. W. 2014, *Headache*, 54(8), 1273-1289.
- Dejaco, C., Brouwer, E., Mason, J. C., Buttgerit, F., Matteson, E. L. and Dasgupta, B. 2017, *Nat. Rev. Rheumatol.*, 13(10), 578-592.
- Ly, K. H., Régent, A., Tamby, M. C. and Mouthon, L. 2010, *Autoimmun. Rev.*, 9(10), 635-645.
- Gonzalez-Gay, M. A., Vazquez-Rodriguez, T. R., Lopez-Diaz, M. J., Miranda-Fillooy, J. A., Gonzalez-Juanatey, C., Martin, J. and Llorca, J. 2009, *Arthritis Rheum.*, 61(10), 1454-1461.
- Taylor-Gjevrev, R., Vo, M., Shukla, D. and Resch, L. 2005, *J. Rheumatol.*, 32(7), 1279-1282.
- Hall, S. and Hunder, G. G. 1984, *Mayo Clin. Proc.*, 59(11), 793-796.
- Murchison, A. P. and Bilyk, J. R. 2012, *Ophthalmology*, 119(12), 2637-2642.
- Siemssen, S. J. 1987, *Br. J. Plast. Surg.*, 40(1), 73-82.
- Schmidt, W. A., Kraft, H. E., Vorpahl, K., Völker, L. and Gromnica-Ihle, E. J. 1997, *N. Engl. J. Med.*, 337(19), 1336-1342.
- Chrysidis, S., Duftner, C., Dejaco, C., Schäfer, V. S., Ramiro, S., Carrara, G., Scirè, C. A., Hocevar, A., Diamantopoulos, A.P., Iagnocco, A., Mukhtyar, C., Ponte, C., Naredo, E., De Miguel, E., Bruyn, G. A., Warrington, K. J., Terslev, L., Milchert, M., D'Agostino, M. A., Koster, M. J., Rastalsky, N., Hanova, P., Macchioni, P., Kermani, T. A., Lorenzen, T., Døhn, U. M., Fredberg, U., Hartung, W., Dasgupta, B. and Schmidt, W. A. 2018, *RMD Open*, 4(1), e000598-000598.

18. Aschwanden, M., Imfeld, S., Staub, D., Baldi, T., Walker, U. A., Berger, C. T., Hess, C. and Daikeler, T. 2015, *Clin. Exp. Rheumatol.*, 33(2 Suppl. 89), S-5.
19. Aschwanden, M., Daikeler, T., Kesten, F., Baldi, T., Benz, D., Tyndall, A., Imfeld, S. and Staub, D. 2013, *Ultraschall. Med.*, 34(1), 47-50.
20. Diamantopoulos, A. P., Haugeberg, G., Hetland, H., Soldal, D. M., Bie, R. and Myklebust, G. 2014, *Arthritis Care Res. (Hoboken)*, 66(1), 113-119.
21. Habib, H. M., Essa, A. A. and Hassan, A. A. 2012, *Clin. Rheumatol.*, 31(2), 231-237.
22. Karahaliou, M., Vaiopoulos, G., Papaspyrou, S., Kanakis, M. A., Revenas, K. and Sfikakis, P. P. 2006, *Arthritis Res. Ther.*, 8(4), R116.
23. Neshet, G., Shemesh, D., Mates, M., Sonnenblick, M. and Abramowitz, H. B. 2002, *J. Rheumatol.*, 29(6), 1224-1226.
24. Reinhard, M., Schmidt, D. and Hetzel, A. 2004, *Rheumatol. Int.*, 24(6), 340-346.
25. Schmidt, W. A., Kraft, H. E., Vorpahl, K., Völker, L. and Gromnica-Ihle, E. J. 1997, *N. Engl. J. Med.*, 337(19), 1336-1342.
26. LeSar, C. J., Meier, G. H., DeMasi, R. J., Sood, J., Nelms, C. R., Carter, K. A., Gayle, R. G., Parent, F. N. and Marcinczyk, M. J. 2002, *J. Vasc. Surg.*, 36(6), 1154-1160.
27. Murgatroyd, H., Nimmo, M., Evans, A. and MacEwen, C. 2003, *Eye (Lond.)*, 17(3), 415-419.
28. Luqmani, R., Lee, E., Singh, S., Gillett, M., Schmidt, W. A., Bradburn, M., Dasgupta, B., Diamantopoulos, A. P., Forrester-Barker, W., Hamilton, W., Masters, S., McDonald, B., McNally, E., Pease, C., Piper, J., Salmon, J., Wailoo, A., Wolfe, K. and Hutchings, A. 2016, *Health Technol. Assess.*, 20(90), 1-238.
29. Pfadenhauer, K. and Weber, H. 2003, *J. Rheumatol.*, 30(10), 2177-2181.
30. Romera-Villegas, A., Vila-Coll, R., Poca-Dias, V. and Cairols-Castellote, M. A. 2004, *J. Ultrasound Med.*, 23(11), 1493-1498.
31. Habib, H. M., Essa, A. A. and Hassan, A. A. 2012, *Clin. Rheumatol.*, 31(2), 231-237.
32. Bley, T. A., Uhl, M., Carew, J., Markl, M., Schmidt, D., Peter, H. H., Langer, M. and Wieben, O. 2007, *Am. J. Neuroradiol.*, 28(9), 1722-1727.
33. Bley, T. A., Weiben, O., Uhl, M., Vaith, P., Schmidt, D., Warnatz, K. and Langer M. 2005, *Arthritis Rheum.*, 52(8), 2470-2477.
34. Geiger, J., Bley, T., Uhl, M., Frydrychowicz, A., Langer, M. and Markl, M. 2010, *J. Magn. Reson. Imaging*, 31(2), 470-474.
35. Klink, T., Geiger, J., Both, M., Ness, T., Heinzlmann, S., Reinhard, M., Holl-Ulrich, K., Duwendag, D., Vaith. and Bley, T. A. 2014, *Radiology*, 273(3), 844-852.
36. Siemonsen, S., Brekenfeld, C., Holst, B., Kaufmann-Buehler, A. K., Fiehler, J. and Bley, T. A. 2015, *Am. J. Neuroradiol.*, 36(1), 91-97.
37. Rhéaume, M., Rebello, R., Pagnoux, C., Carette, S., Clements-Baker, M., Cohen-Hallaleh, V., Doucette-Preville, D., Jackson, B. S., Salama, S. S. S., Ioannidis, G. and Khalidi, N. A. 2017, *Arthritis Rheumatol.*, 69(1), 161-168.
38. Dejaco, C., Ramiro, S., Duftner, C., Besson, F. L., Bley, T. A., Blockmans, D., Brouwer, B., Cimmino, M. A., Clark, E., Dasgupta, B., Diamantopoulos, A. P., Direskeneli, H., Iagnocco, A., Klink, T., Neill, L., Ponte, C., Salvarani, C., Slart, R. H. J. A., Whitlock, M. and Schmidt, W. A. 2018, *Ann. Rheum. Dis.*, 77(5), 636-643.
39. Lariviere, D., Benali, K., Coustet, B., Pasi, N., Hyafil, F., Klein, I., Chauchard, M., Alexandra, J. F., Goulenok, T., Dossier, A., Dieude, P., Papo, T., Sacre, K. 2016, *Medicine (Baltimore)*, 95(30), e4146.
40. Blockmans, D., Stroobants, S., Maes, A. and Mortelmans L. 2000, *Am. J. Med.*, 108(3), 246-249.
41. Yuge, S., Nakatani, K., Yoshino, K. and Koyama, T. 2018, *Ann. Nucl. Med.*, 32(8), 573-577.
42. Ponte, C., Grayson, P., Suppiah, R., Robson, J., Gribbons, K., Craven, A., Khalid, S., Judge, A., Hutchings, A., Watts, R., Merkel, P. and Luqmani, R. 2019, *Rheumatology (Oxford)*, <https://doi.org/10.1002/acr.24055>
43. Serling-Boyd, N. and Stone, J. H. 2020, *Curr. Opin. Rheumatol.*, 32(3), 201-207.
44. Lyons, H. S., Quick, V., Sinclair, A. J., Nagaraju, S. and Mollan, S. P. 2020, *Eye (Lond.)*, 34(6), 1013-1026.
45. British Medical Journal. BMJ Best Practice. Critical appraisal checklists. Accessed 17/07/, 2020. Available at: <https://bestpractice.bmj.com/info/toolkit/ebm-toolbox/critical-appraisal-checklists/>.